


CASE REPORT

Open Access



Delayed intestinal obstruction from an unintentionally retained surgical gauze in a 24-year old woman two years after caesarean section: a case report

Samir Ismail Bashir¹, Yasir Babiker Ali¹, Elsadig Mohamed Ali², Hiba Awadelkareem Osman Fadl^{3,4}, Abdelrahman Hamza Abdelmoneim Hamza^{5,6} and Mohammed Mahmmod Fadelallah Eljack^{7,8*} 

Abstract

Background One of the most common surgical emergencies, intestinal obstruction is rarely the result of an inadvertently retained foreign object (also known as a gossypiboma), which may not present symptoms for a lifetime. It also carries additional legal burdens, which may account for the rarity of its reports.

Case presentation We report a 24-year-old Sudanese female with a history of emergency Caesarean section two years before the admission presented with abdominal distension and absolute constipation, which was diagnosed as intestinal obstruction with a retained gauze found within the small intestine. Moreover, a review of recent African-reported cases was done to find relatively similar cases.

Conclusion Adhering to the standard of care in surgical theaters and integrating new methods of prevention like tagged gauze could help to decrease the rate of such cases in the future.

Keywords Gossypiboma, Surgical sponges, Intestinal obstruction, Laparotomy, Foreign body

*Correspondence:

Mohammed Mahmmod Fadelallah Eljack
m.mahmmoud96@gmail.com

¹Department of Surgery, Faculty of Medicine and Health Sciences, University of Bakht Alruda, Ad Duwaym, Sudan

²General Surgery Resident, Medical Specialization Board (SMSB), Khartoum, Sudan

³Department of Haematology, Faculty of Medical Laboratory Sciences, Al-Neelain University, Khartoum, Sudan

⁴Haematology First Specialist, Medical Laboratory, Sudanese National Council for Medical & Health Professions (SNCMHP), Khartoum, Sudan

⁵Clinical Immunology Resident, Medical Specialization Board (SMSB), Khartoum, Sudan

⁶Faculty of Medicine, Al-Neelain University, Khartoum, Sudan

⁷Faculty of Medicine, University of Bakht Alruda, Ad Duwaym, Sudan

⁸Community department, University of Bakht Alruda, University of Bakht Alruda, Ad Duwaym, Ad Duwaym, Sudan

Introduction

Forgetting a foreign body such as a mass of cotton material, sponges' gauze, towels, or even instruments is one of the worst misadventures that a surgeon could ever have, which comes with several legal and social consequences [1] [2]. For this condition, the term gossypiboma (derived from *Gossypium* for "cotton" and *Boma* for "a place of concealment") is commonly used [3]. While it is still one of the main causes of intestinal obstruction, exact incidences are unknown (roughly estimated as 1 out of 1000–1500 intra-abdominal operations) [3]. This could be because they are rarely reported in the literature or because sometimes there is not enough documentation in cases that have been diagnosed [4]. As a result, we can assume that the published reports of this technical



© The Author(s) 2023. **Open Access** This article is licensed under a Creative Commons Attribution 4.0 International License, which permits use, sharing, adaptation, distribution and reproduction in any medium or format, as long as you give appropriate credit to the original author(s) and the source, provide a link to the Creative Commons licence, and indicate if changes were made. The images or other third party material in this article are included in the article's Creative Commons licence, unless indicated otherwise in a credit line to the material. If material is not included in the article's Creative Commons licence and your intended use is not permitted by statutory regulation or exceeds the permitted use, you will need to obtain permission directly from the copyright holder. To view a copy of this licence, visit <http://creativecommons.org/licenses/by/4.0/>. The Creative Commons Public Domain Dedication waiver (<http://creativecommons.org/publicdomain/zero/1.0/>) applies to the data made available in this article, unless otherwise stated in a credit line to the data.

oversight are only scratch the surface regarding the actual magnitude of this phenomenon [4].

The most common causes are emergency surgery, unplanned changes in operation, high body mass index, hurried sponge counts, long operations, unstable patient conditions, and inexperienced staff numbers [5]. Even though risk can not be totally eliminated, adhering to good intraoperative surgical practices like sponge counting are usually believed to alleviate the problem [5].

While this condition typically presents with nonspecific clinical features, the patient may experience symptoms for the rest of his life. Moreover, it has the potential to cause serious clinical consequences like ileus, abscess, fistula, and bowel necrosis [6]. Rarely, it may transigrate into the gastrointestinal lumen without any defects, allowing it to exit the body through the intestines, otherwise Laparoscopic or open surgery would be necessary to remove it [7].

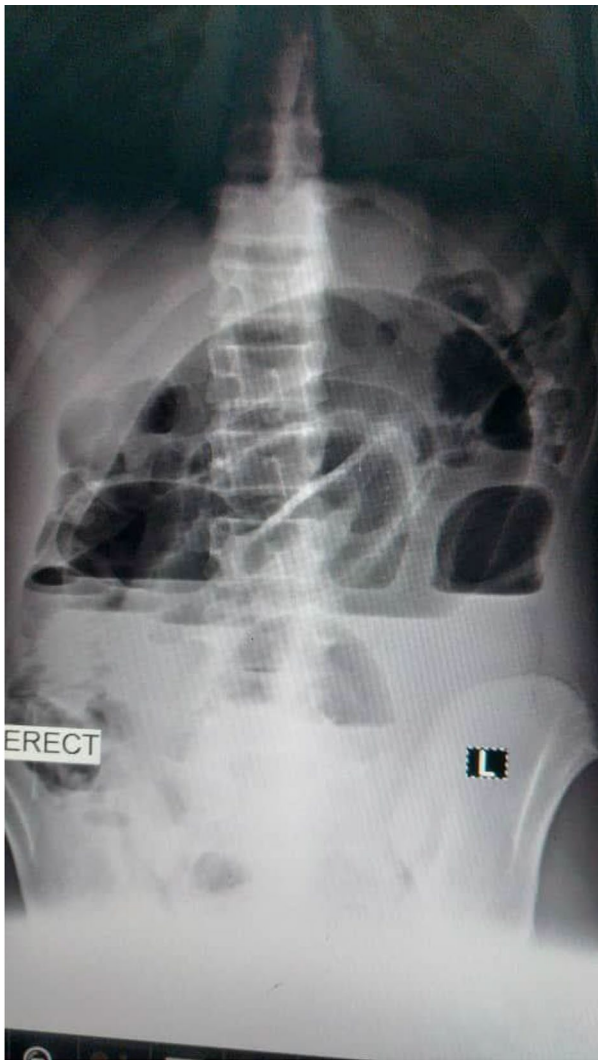


Fig. 1 Erect abdominal x-ray revealed multiple air-fluid levels

Here we present a Sudanese female with a history of emergency Caesarean section presented with intestinal obstruction features, which was found to be due to a gossypiboma formation.

Case presentation

A 24-year-old female, gravida 2, para 2, who had previously undergone a Caesarean section at a rural hospital two years ago, arrived at the emergency room with a gradual onset of abdominal distension, abdominal pain, and absolute constipation for two days. She also experienced nausea and frequent vomiting of greenish material however, there is no fever, burning urination, or chest pain. There was no history of renal colic or intestinal obstruction.

The patient was vitally stable upon examination. The abdomen was distended with mildly generalized tenderness, but there was no guarding or rigidity. Superficial palpation revealed no abnormalities, but deep palpation revealed a globular mass on the left iliac fossa (pedunculated) with clearly defined edges. On auscultation bowel sounds were present.

TWBCs were 8.1, hemoglobin was 9.8, random blood glucose was 99 mg/dl, platelets were 329, blood urea was 27, serum creatinine 0.7, the c-reactive protein was 27, serum potassium was 3.3 mmol/l, abdominal ultrasound was normal, erect abdominal x-ray revealed multiple air-fluid levels (Fig. 1), while supine revealed a dilated loop of the small intestine. A diagnosis of intestinal obstruction was made, and the patient was optimized before being taken to the theatre. Under general anesthesia with tracheal intubation, a midline incision was made with a scalpel, and unipolar diathermy subcutaneous tissue was cut, the muscle was separated, and intraoperative findings showed that the small intestines were found to be adhesively obstructed by a pink mass attached to the jejunum on two closed sites (hanging on it) with serosal attachment, it was firm on consistency measured 10×10 cm as illustrated in Fig. 2. The adhesion was released by scissors and the serosal layer was closed by interrupted sutures, then the intestinal and the abdominal cavity was washed, after which, the drain was placed on the pelvic cavity and then the wound closed in layers.

The macroscopic examination revealed a cyst filled with gauze, while the histopathological examination demonstrated gauze material surrounded by fibromuscular connective tissue and mature adipose tissue, with foci of mixed inflammatory cellular infiltration and foreign body giant cell reaction but no malignant features.

The patient received one unit of blood without complications, in the postoperative course the patient was nil per mouth, and receive intravenous fluids and antibiotics for five days. The patient was vitally stable on follow up, with good urine output, and the drain was removed

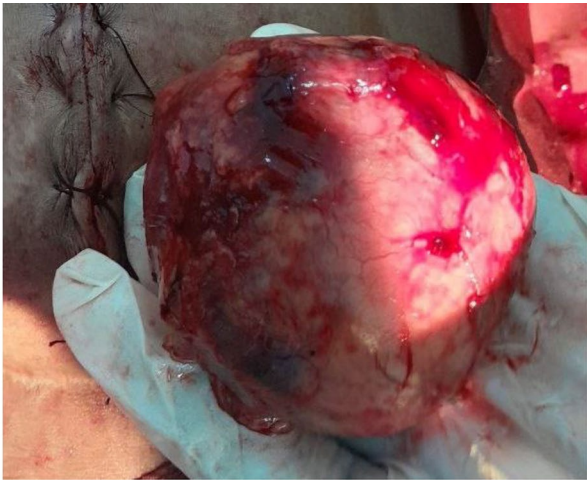


Fig. 2 A pink mass attached to the jejunum on two sites causing mechanical intestinal obstruction

on the fourth day. The patient was discharged on the fifth day and scheduled to see a referring clinic two weeks later.

Discussion and literature review

Despite being a well-described phenomenon in the surgical world, Gossypiboma is still a frequent problem in multiple countries. This could be partly because not all cases are presented with immediate post-surgical symptoms. Some patients presented after several years due to the delayed non-inflammatory reaction of the body to the retained gauze. Furthermore, although in our case x-rays showed abnormal signs indicating a possible bowel obstruction, regular abdomen X-ray usually doesn't provide conclusive evidence of the underline existing gossypiboma. That is why CT- abdomen is considered the preferred choice in such cases.

The present study focuses on intestinal obstruction caused by gossypiboma and reported in African countries ten years ago. All cases are females. This may be because they are more exposed to surgical operations due to obstetric surgery.

Several reviews were reported regarding Gossypiboma, one of these reports was written by Wan et al., about retained surgical sponges, which were found in the abdomen in (56%) of the cases. It was commonly detected using computed tomography (61%) and radiography (35%). Furthermore, the median discovery time was of 2.2 years, all of which go in line with the characteristic of our case [8] [13].

Another review was done in Sudan by Suliman et al. and published in 2013, which reviewed several local cases of Gossypiboma in Sudanese females after cesarean section. Which presented with signs of infection and bowel obstruction and required surgical intervention to remove

the retained surgical gauze. Luckily all the patients in this report survived until discharge from the hospital [9].

Likewise, Yorke et al. reported a case of intestinal obstruction due to an intraluminal foreign body. In this case, a patient underwent a laparotomy to treat ruptured acute appendicitis. A laparotomy towel was left behind during the operation [10]. In addition, as reported by Emegoakor et al. in Nigeria in 2021 a 28-year-old woman, following an open myomectomy in a private hospital, suffered from colicky abdominal pain, distention, and a mass for 9 months [11]. both patients in this study had similar complications of intestinal obstruction which was the same fate of our patient.

A similar course of events was noticed in the post-myomectomy case reported by Naiem et al. in 2021 which presented with acute abdominal signs after almost 6 months of the primary operation and it was then discovered to be due to infected missed surgical gauze that was then extracted with good patient outcome [12].

For such cases and once the diagnosis has been made, management includes investigations, parenteral antibiotics, intravenous fluids, and emergency laparotomies. In addition, laparoscopic retrieval may also be carried out if the diagnosis is done early [13, 14].

Medical practitioners, especially surgical staff, must be aware of the risk factors that cause retained sponges and take deliberate steps to avoid them [2, 15, 16]. This could involve Keeping a detailed pack and instrument count at the beginning and the end of the surgery, performing a thorough methodical wound examination and abdominal exploration before closure and performing intraoperative radiologic screening or re-exploration when there is a doubt about the accuracy of the final count [17]. A high suspicion index is needed to diagnose gossypiboma and implement prompt interventions to reduce patient morbidity and mortality [16].

One of the promising solutions to decrease the rate of Gossypiboma is the use of tagged surgical gauze which can be detected by regular x-ray. This is expected to decrease the rate of error associated with the use of manual counting (Table 1).

Conclusion

Gossypiboma should be considered even though it is rare in patients with intestinal obstruction, especially if there is a history of abdominal surgery, as it can have serious consequences. To reduce its occurrence and medico-legal ramifications, standard surgical precaution and prevention measures should always be followed, including pre- and post-operative sponge counting, the use of radio-opaque markers, and ongoing staff training.

Table 1 Summary of intestinal obstruction cases that caused by gossypiboma and reported in African countries ten years ago

Author	Number of cases	Patients ages	Gender	Type of operation	Clinical presentation	Type of post-operative complications	Time to presentation	Possible causes
Suliman et al.2013 (9)	3	Between 24 and 32 years.	females.	Caesarean section	Abdominal pain, and vomiting	Infections. Small bowel obstruction. Discharged in good condition	5 months to 2 years	NAD
Yorke et al. 0.2019(10)	1	62	female	Appendicitis	Abdominal pain and distension, constipation and vomiting	Infections. bowel obstruction. Discharged in good condition	17 months	NAD
Emegoakor et al. 2021 (11)	1	28	female	myomectomy	Abdominal pain and distension, nausea and occasional diarrhea	Infection, Partial bowel obstruction. Discharged in good condition	9 months	NAD
Naiem e al. 2021 (12)	1	37	female	myomectomy	Abdominal pain, fever, and vomiting	Infections. Bowel obstruction. Discharged in good condition	6 months	NAD
Current case	1	24	female	Caesarean section	Fever, Abdominal pain, distension and constipation	Bowel obstruction. Discharged in good condition	24 months	NAD

Acknowledgements

N/A.

Author contributions

S.I.B, Y.B.A, E.M.A : wrote the main manuscript text.H.A.O, A.H.A, M.M.F: Prepared figuresAll authors reviewed the manuscript.

Funding

The study was self-funded.

Data Availability

The data set used and/or analyzed during the study are available from the corresponding author on reasonable request.

Declarations**Ethical approval and Consent to participate**

We confirm that all methods were carried out in accordance with relevant guidelines and regulations. the participants provided verbal and written informed consent. Participant was assured about the confidentiality of any obtained information. The data from this case was managed only by researchers in this study, Results will be used only for research and data cannot be traced back to their original sources.

Consent for publication

Verbal and written informed consent to publication was obtained from the patient.

Competing interests

Authors declared no competing of interest.

Received: 20 April 2023 / Accepted: 13 July 2023

Published online: 21 July 2023

References

- Shenoy A, Shenoy GN, Shenoy GG. Patient safety assurance in the age of defensive medicine: a review. *Patient Saf Surg.* 2022;16:10.
- Lembitz A, Clarke TJ. Clarifying “never events” and introducing “always events. *Patient Saf Surg.* 2009;3:26.
- Garg M, Marwah S, Sethi D, Kataria SP. Acute abdomen by gossypiboma. *Annals of Tropical Medicine and Public Health.* 2012;5:511.
- Margonis E, Vasdeki D, Diamantis A, Koukoulis G, Christodoulidis G, Tepetes K. Intestinal obstruction and Ileocolic Fistula due to Intraluminal Migration of a Gossypiboma. *Case Rep Surg.* 2016;2016:3258782.

- Khan AZ, Fatima T, Kafeel U, Afzal MF, Asif S, Ghumman AR. Preventable morbidities of a successful intervention, Textiloma/Gossypiboma: a case series. *J Pak Med Assoc.* 2023;73(4):888–91.
- Tchangai B, Tchaou M, Kassegne I, Simlawo K. Incidence, root cause, and outcomes of unintentionally retained intraabdominal surgical sponges: a retrospective case series from two hospitals in Togo. *Patient Saf Surg.* 2017;11(1):25.
- Aydogan A, Akkucuk S, Yetim I, Ozkan OV, Karcioglu M. Gossypiboma causing mechanical intestinal obstruction: a Case Report. *Case Rep Surg.* 2012;2012:543203.
- Ahmed A, Lohiya S. A Retained Foreign Body as a Rare Cause of Small Bowel Obstruction (Gossypiboma): A Case Report. *Cureus.* 2023 Apr 05;15(4):e37185. doi: <https://doi.org/10.7759/cureus.37185>.
- Suliman sh, Oe S, Dabora A. Transmural Migration of Retained Surgical Sponges into the Bowel after Caesarian Section: Case Series and Literature Review. *Sudan Med J.* 2013;49:176–82.
- Yorke J, Awoonor Williams R, Ansong G, Hammond B, Boateng E, Gyamfi F, et al. Intestinal obstruction secondary to Intra-Luminal retained Laparotomy Towel: a Case Report. *Int J Surg Res Pract.* 2019;6:104.
- Emegoakor C, Nzeako H, Ugwuanyi K, Okafor C, Ijezie A. Retained surgical sponge presenting as a case of intestinal obstruction. *World J Adv Res Reviews.* 2021;10:412–6.
- Naiem MEA, Suliman SH, Elgurashi MEA, Arabi NA, Mohammedkhair AAA, Nafi HMO. Small bowel obstruction and ileocolic fistula caused by post-myomectomy Gossypiboma transmural migration: a case report and review of the literature. *Int J Surg Case Rep.* 2021 Oct;87:106431. <https://doi.org/10.1016/j.ijscr.2021.106431>.
- Steelman VM, Shaw C, Shine L, et al. Retained surgical sponges: a descriptive study of 319 occurrences and contributing factors from 2012 to 2017. *Patient Saf Surg.* 2018;12:20. <https://doi.org/10.1186/s13037-018-0166-0>.
- Bello U, Muktar U, Ismail N. Retained gauze in the abdomen following prior laparotomy. *Nigerian J Basic Clin Sci.* 2021;18(2):153–5.
- Patil KK, Patil Sk Fau - Gorad KP, Gorad Kp Fau - Panchal AH, Panchal Ah Fau - Arora SS, Arora Ss Fau - Gautam RP, Gautam RP. Intraluminal migration of surgical sponge: gossypiboma. (1998–4049 (Electronic)).
- Weprin S, Crocerossa F, Meyer D, Maddra K, Valancy D, Osardo R, Kang HS, Moore RH, Carbonara U, Kim J, Autorino F. Risk factors and preventive strategies for unintentionally retained surgical sharps: a systematic review. *Patient Saf Surg.* 2021;15:24.
- Regenbogen SE, Greenberg CC, Resch SC, Kollengode A, Cima RR, Zinner MJ, et al. Prevention of retained surgical sponges: a decision-analytic model predicting relative cost-effectiveness. *Surgery.* 2009;145(5):527–35.

Publisher's Note

Springer Nature remains neutral with regard to jurisdictional claims in published maps and institutional affiliations.